


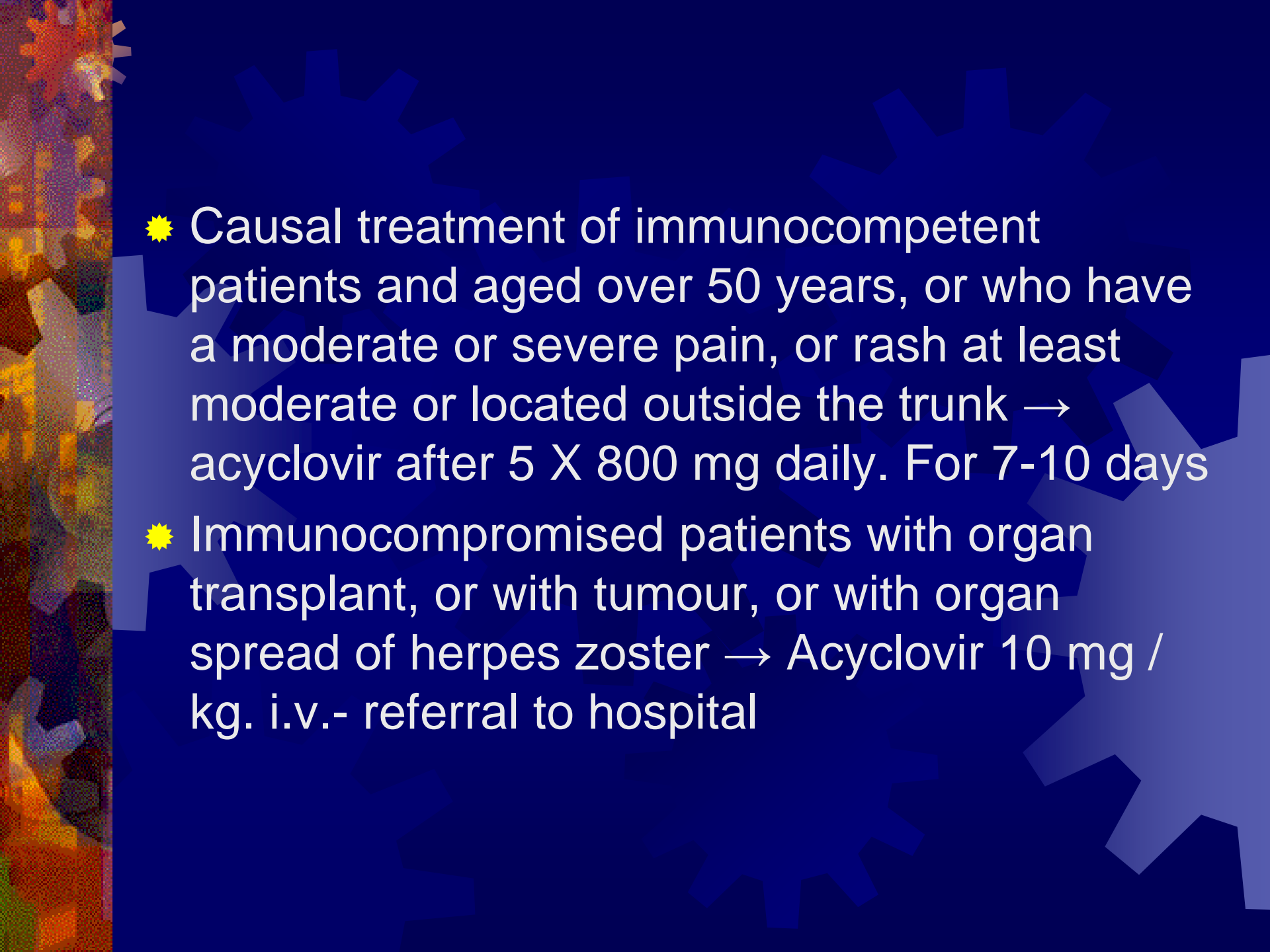
A 60 - year-old patient reported due to heavy, stinging pain in the subscapular area escalating during deep breathing and coughing, and itching of the skin in the area.



In the subscapular area right along the course of the ribs, eruptions of a bubble on the erythematous ground

VZV causes chickenpox and shingles

- ★ An adult suffering from shingles can infect the baby. Shingles is less contagious than chicken pox, but after contact with herpes zoster about 20-40% of people susceptible to infection become sick (i.e. 1-2 for every 5 people).
- ★ The most infectious is fluid contained in the vesicles.

- 
- ★ Causal treatment of immunocompetent patients and aged over 50 years, or who have a moderate or severe pain, or rash at least moderate or located outside the trunk → acyclovir after 5 X 800 mg daily. For 7-10 days
 - ★ Immunocompromised patients with organ transplant, or with tumour, or with organ spread of herpes zoster → Acyclovir 10 mg / kg. i.v.- referral to hospital

Prevention

- ★ VZV vaccination reduces the risk of herpes zoster in the vaccinated persons, although we do not know exactly to what extent
- ★ The vaccine (Varilrix): includes attenuated virus capable of replication, it belongs to the category of "living".
- ★ against shingles - a vaccine for persons > 60 years of age